

## ***NR1H4*-related Progressive Familial Intrahepatic Cholestasis 5: Further Evidence for Rapidly Progressive Liver Failure**

Ryan W. Himes<sup>1\*</sup>, Majid Mojarad<sup>2,3\*</sup>, Atieh Eslahi<sup>2,3</sup>, Milton J. Finegold<sup>4</sup>, Reza Maroofian<sup>5</sup>,  
David D. Moore<sup>6</sup>

<sup>1</sup> Section of Pediatric Gastroenterology and Hepatology, Ochsner Medical Center, New Orleans, USA

<sup>2</sup> Department of Medical Genetics, School of Medicine, Mashhad University of Medical Sciences, Iran

<sup>3</sup> Medical Genetics Research Center, Faculty of Medicine, Mashhad University of Medical Sciences, Mashhad, Iran

<sup>4</sup> Department of Pathology, Baylor College of Medicine, Houston, USA

<sup>5</sup> Genetics Research Centre, Molecular and Clinical Sciences Institute, St George's, University of London, Cranmer Terrace, London SW17 0RE, UK

<sup>6</sup> Department of Molecular and Cellular Biology, Baylor College of Medicine, Houston, USA

\* Denotes equal contributions to the manuscript

*Corresponding Author:* Ryan W. Himes, 1514 Jefferson Hwy, New Orleans, LA 70121

[ryan.himes@ochsner.org](mailto:ryan.himes@ochsner.org), Ph-504-842-3900, Fax-504-842-0160

*Conflicts of Interest and Sources of Funding:* The authors have no relevant conflicts of interest to disclose. No extramural funding was obtained for this work.

### **Author Contributions**

Ryan W. Himes-drafted initial manuscript, approval of final version.

Majid Mojarrad-revisions of manuscript drafts, approval of final version.

Atieh Eslahi- revisions of manuscript drafts, approval of final version.

Milton J. Finegold-revisions of manuscript drafts, approval of final version.

Reza Maroofian-drafted initial manuscript, approval of final version.

David D. Moore- revisions of manuscript drafts, approval of final version.

## Abstract

Pathogenic sequence variants in the nuclear bile acid receptor FXR, encoded by *NR1H4*, have been reported in a small number of children with low-GGT cholestasis progressing to liver failure. We describe three additional children from two unrelated families with cholestasis and liver failure due to pathologic variants in *NR1H4*. One patient underwent liver transplantation and has had good clinical outcomes in six years of follow-up. While that patient has biochemical evidence of increased bile acid synthetic activity, he has not experienced post-transplant diarrhea or allograft steatosis, as has been reported among other transplanted patients.

**Keywords:** pediatric, coagulopathy, bile acids, jaundice, hyperbilirubinemia

## What is known?

- Pathogenic sequence variants in *NR1H4* are associated with low-GGT cholestasis and liver failure.
- Liver transplantation may offer effective rescue of liver failure, but transplanted patients might have residual biochemical and clinical abnormalities owing to extrahepatic FXR expression.

## What is new?

- A strict genotype-phenotype correlation may not exist for this condition.
- Increased bile acid synthesis observed among transplanted patients is not universally associated with evidence of allograft injury.

## Introduction

An advance in our understanding of intrahepatic cholestasis came when the molecular underpinnings of the syndromes known as progressive familial intrahepatic cholestasis (PFIC) type 1, PFIC2, and PFIC3 were found to be due to pathogenic variants in *ATP8B1*, *ABCB11*, and *ABCB4*, respectively. In 2014, pathogenic variants in *TJP2* were linked to low-GGT cholestasis and termed PFIC4 [1]. In 2016, four patients in two families with low-GGT cholestasis progressing to liver failure were described as having loss-of-function mutations in the nuclear bile acid receptor FXR, encoded by *NR1H4*, a disease subsequently designated PFIC5 [2]. Since then, only one additional child with PFIC5 has been reported [3]. Herein, we describe three additional children from two unrelated families with cholestasis and liver failure due to pathologic variants in *NR1H4*.

### Family 1, Patient 1

A 17-month-old Hispanic male was brought to medical attention for jaundice and abdominal distention. He was the product of an uncomplicated term pregnancy to a 22-year-old primigravida. The patient was normally developing; there was no family history of liver disease, however, the child's parents were consanguineous.

On examination, the patient appeared well-nourished (weight 79<sup>th</sup> centile, length 47<sup>th</sup> centile, weight-for-length 91<sup>st</sup> centile), jaundiced, and his abdomen was distended, with liver and spleen palpable ~5 cm below the costal margins. Initial laboratory testing is shown in Table 1.

Abdominal ultrasonography demonstrated splenomegaly and chest radiography revealed generalized osteopenia, but no evidence for fractures.

A diagnostic evaluation was unrevealing, so a liver biopsy was performed which showed

micronodular cirrhosis and complete absence of BSEP protein along the canaliculus (Figure 1), while MDR3 expression was preserved, raising the possibility of *ABCB11*-related PFIC2.

*ABCB11* gene sequencing, however, was normal.

The patient was treated with parenteral vitamin K, ursodeoxycholic acid, spironolactone, and lactulose. He was hypoglycemic while feeding orally, so dextrose-containing intravenous fluids were initiated along with nasogastric tube feedings. After two weeks, his weight gain was suboptimal and he continued to require intravenous dextrose, so parenteral nutrition was started. He was evaluated and approved for liver transplantation, undergoing deceased donor liver transplant 11 weeks after his initial presentation, at 20 months of age. Laboratory testing just before transplant reflected deterioration (Table 1). His post-operative course included systemic hypertension and development of posterior reversible encephalopathy syndrome, which was treated with a change from tacrolimus to sirolimus, antihypertensives, and an antiepileptic. He had an episode of early acute cellular rejection which was treated satisfactorily with steroids.

Four years after the patient was transplanted, Gomez-Ospina *et al* described *NR1H4* sequence variants in patients with low-GGT, intrahepatic cholestasis [2]. Because their patients exhibited lack of BSEP staining on liver immunohistochemistry, but no evidence for pathologic *ABCB11* sequence variants, like our patient, we pursued trio whole exome sequencing. A homozygous pathogenic variant in *NR1H4* (c.526C>T, p.R176X) was found in the proband and confirmed to be in trans-configuration. Immunostain on retained explanted liver showed complete absence of FXR expression in hepatocytes (Figure 1).

Six years post-transplant, the patient has continued to do well clinically. He has not experienced diarrhea and somatic growth is normal. Liver indices have been stably normal on sirolimus

monotherapy. Four liver biopsies in the first two post-transplant years showed no significant steatosis. Assessment of the bile acid synthesis pathway revealed normal total cholesterol (124 mg/dL), elevated 7- $\alpha$ -OH-4-cholesten-3-one (C4) (0.81  $\mu$ mol/L, nl 0.02-0.05  $\mu$ mol/L) and chenodeoxycholic acid (0.78  $\mu$ mol/L, nl 0.07-0.23  $\mu$ mol/L), but normal cholic acid (0.11  $\mu$ mol/L, nl 0.03-0.25  $\mu$ mol/L).

### **Family 2, Patient 2**

A 1-month-old female of Persian descent presented with jaundice, poor growth, and respiratory distress associated with a pleural effusion. She was the full-term product of a consanguineous (first cousins) union. Initial laboratory testing is shown in Table 1. Diagnostic tests showed normal thyroid stimulating hormone, 17-OH-progesterone, galactose-1 phosphate uridyl transferase, succinylacetone, and biotinidase. There was no biochemical evidence for disorders of  $\beta$ -oxidation of fatty acids, carnitine metabolism, organic acidemia, or urea cycle defects. Plasma amino acid profile showed elevations of tyrosine, methionine and galactose interpreted as reflective of hepatic dysfunction.

She experienced a progressive course with increasing jaundice, hypoglycemia, and hyperammonemia (Table 1). She died at 8-months-of-age due to multiorgan failure.

### **Family 2, Patient 3**

Two-and-a-half years later, a 1-week-old male of the same union was admitted with jaundice, poor growth, and respiratory distress. Like his sister, he was born at term and appeared well at birth. Exam revealed the liver and spleen palpable 2 cm below the costal margins. Initial laboratory testing is shown in Table 1. Ultrasound of the right upper quadrant was normal, however, ultrasound of the chest showed a large, right, pleural effusion. Diagnostic evaluation

reveled elevated plasma tyrosine. No succinylacetone was detected, however, and genetic testing for tyrosinemia was also normal. The patient was treated supportively with autologous serum therapy, fresh frozen plasma, and supplemental fat-soluble vitamins, but experienced progressive deterioration (Table 1). Whole exome sequencing was performed which demonstrated a homozygous, out-of-frame insertion, in *NR1H4* (c.276dupT, p.P93Sfs\*4). He died at 7-months-of-age due to liver failure.

## Discussion

We have described 3 patients from 2 unrelated families with *NR1H4* disease. In contrast to most reported patients, Patient 1 had a later onset of illness (16 months) and failure-to-thrive was not a presenting sign. However, like other patients, his course was marked by progressive jaundice, low GGT, vitamin K-refractory coagulopathy, and absence of BSEP staining on liver tissue. Patient 1 has the same homozygous *NR1H4* variant reported in Family 1 from the Gomez-Ospina paper, in which both patients had much earlier onset, so a strict genotype-phenotype correlation may not exist. Patient 1 also underwent liver transplantation but has not developed allograft steatosis or liver test abnormalities, in spite of having elevated plasma bile acid precursor C4 post-transplantation, like the transplanted patients in the literature. The increase in bile acid synthesis in these allografts likely relates to loss of FGF19-mediated feedback inhibition on hepatic CYP7A1 stemming from residual loss of the *NR1H4* gene product (FXR) in the native intestine. Patient 1 provides additional evidence that extrahepatic (e.g. gut, kidney) *NR1H4* may not be essential since he has not developed a clinical abnormality in either organ system more than 6 years post-transplant.

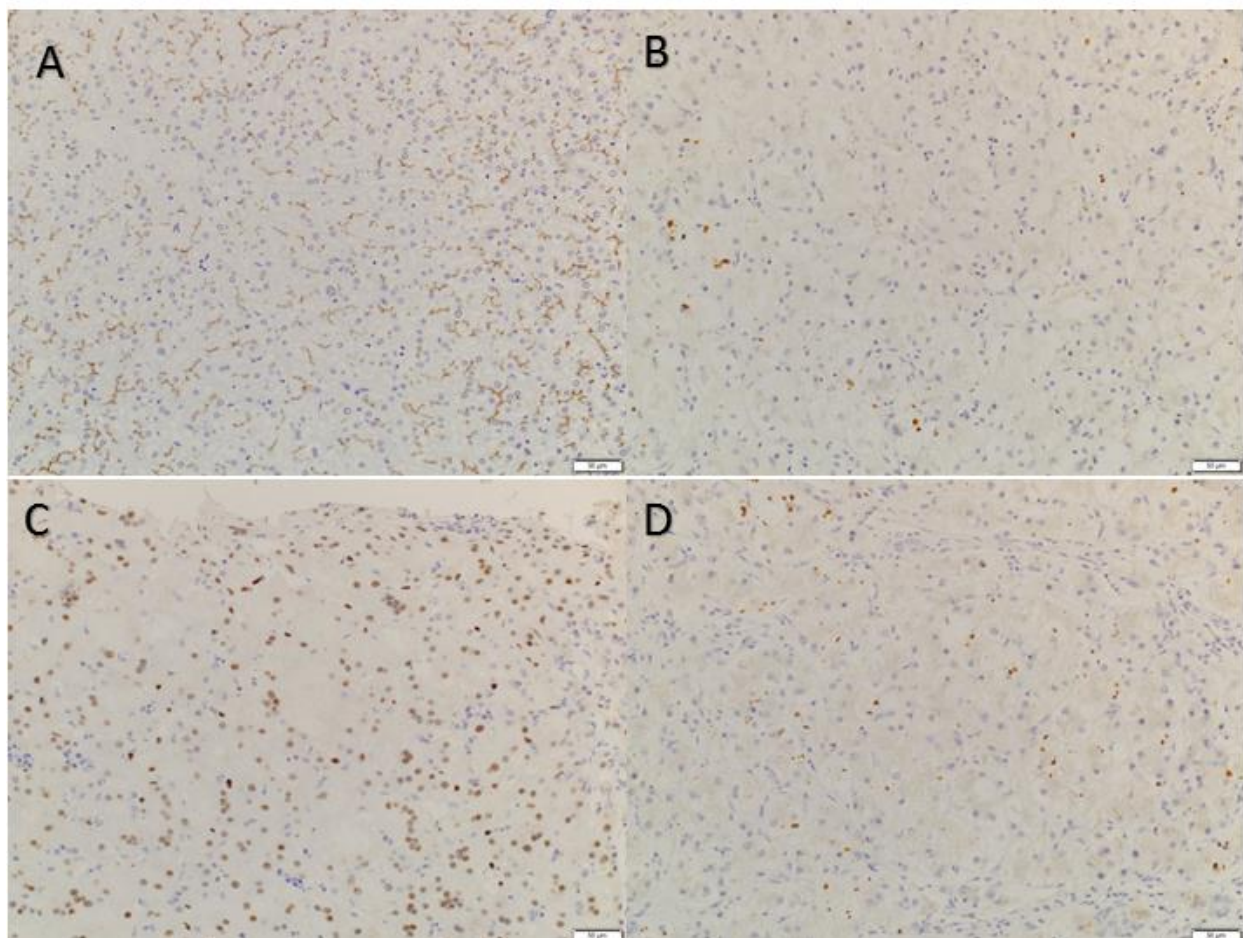
Regarding Family 2, Patients 2 and 3 presented with strikingly similar clinical features and both succumbed to progressive liver disease before the 1<sup>st</sup> birthday. While less clinical and laboratory data was available for these patients, what is reported is consistent with other patients in the literature. The nature of the pleural effusions in these patients, as well as those in the literature [2], is not entirely clear, but that it was documented on the right side in Patient 3, may suggest hepatic hydrothorax, a common finding among patients with cirrhosis. Patient 2 died before definitive molecular diagnostics could be obtained, however, whole exome sequencing of Patient 3 demonstrated a novel, homozygous, out-of-frame insertion in *NR1H4* (c.276dupT, p.P93Sfs\*4) which is predicted to lead to premature termination of protein translation.

*NR1H4*-related PFIC5 is a rapidly progressive disease, the natural history of which is not modified by medical interventions. Liver transplantation, on the other hand, appears to provide a satisfactory outcome, with reasonably long follow-up among the small number of patients who have been transplanted. While this is reassuring, it seems prudent to counsel families of children with PFIC5 being considered for liver transplantation about the extrahepatic expression of *NR1H4* as well as the unknowns of gut-liver signaling following transplantation. Based on the broad differential diagnosis for these patients and limited time in which to make important therapeutic decisions, we would advocate for early use of *NR1H4* sequencing, or unbiased molecular diagnostics like whole exome sequencing, provided results can be available to the clinical team promptly.



## References

1. Sambrotta M, Strautnieks S, Papouli E, Rushton P, Clark BE, Parry DA, et al. Mutations in TJP2 cause progressive cholestatic liver disease. *Nat Genet.* 2014 Apr;46(4):326–8.
2. Gomez-Ospina N, Potter CJ, Xiao R, Manickam K, Kim M-S, Kim KH, et al. Mutations in the nuclear bile acid receptor FXR cause progressive familial intrahepatic cholestasis. *Nat Commun.* 2016 Feb 18;7:10713.
3. Chen H-L, Li H-Y, Wu J-F, Wu S-H, Chen H-L, Yang Y-H, et al. Panel-Based Next-Generation Sequencing for the Diagnosis of Cholestatic Genetic Liver Diseases: Clinical Utility and Challenges. *J Pediatr.* 2018 Oct 23.



**Figure 1-** Liver immunostain. BSEP normal control (A), and explant of Patient 1 (B). FXR normal control (C), and explant of Patient 1 (D).

**Table 1** Summary of clinical and laboratory findings

	Family 1		Family 2			
	Patient 1		Patient 2		Patient 3	
Sex	Male		Female		Male	
Age at onset	16 months		3 weeks		1 week	
Age at initial evaluation	17 months		1 month		29 days	
Age at liver transplant	20 months		NA		NA	
Age at last evaluation	8 years		died at 8 months		died at 7 months	
Signs	Jaundice, abdominal distention		Jaundice, FTT, respiratory distress, pleural effusion		Jaundice, FTT, respiratory distress, pleural effusion	
Liver Biochemistry	Initial evaluation	Before OLT	Initial evaluation	Prior to death	Initial Evaluation	Prior to death
Direct/Conjugated Bilirubin (nl <0.3 mg/dL)	11.3	37	5	8.3	8	8.3
AST (nl <60 U/L)	627	291	71	200	78	193

ALT (nl <45 U/L)	383	302	49	69	51	71
GGT (nl 10-19 U/L)	81	72	NM	NM	NM	NM
AFP (nl 8-468 ng/mL)	9,610	NM	NM	NM	>100,000	NM
Ammonia (nl 22-48 $\mu$ mol/L)	64	84	NM	NM	93	193
<b>Coagulation Parameters</b>						
PT (nl 12.9-16.9 sec)	21.8	26.1	NM	NM	15	NM
INR (nl 0.9-1.1)	1.9	2.4	NM	NM	1.25**	NM
Factor V Assay (nl 69-132%)	38	26	NM	NM	NM	NM
Factor VII Assay (nl 58-150%)	20	13	NM	NM	NM	NM
Platelets (nl 150-450 $\times 10^3/\mu$ L)	103	52	NM	NM	308	190
<p>FTT failure to thrive; AST aspartate aminotransferase; ALT alanine aminotransferase; GGT, g-glutamyl transferase; AFP alpha-fetoprotein; OLT, orthotopic liver transplant; PT prothrombin time; INR international normalized ratio; NA not applicable; MN not measured; nl normal; ** The values obtained were not representative due to transfusions of blood products.</p>						